

Penile Metastasis from Prostate Cancer: Detection on 18F-PSMA-1007 PET/CT

Item author(s)	Komber, Hend;Nawwar, Ayah;Searle, Julie;Lyburn, Iain
Item title	Penile Metastasis from Prostate Cancer: Detection on 18F-PSMA-1007 PET/CT
Citation	Komber, H., Nawwar, A., Searle, J., & Lyburn, I. (2025). Penile Metastasis from Prostate Cancer: Detection on 18F-PSMA-1007 PET/CT. <i>Molecular imaging and radionuclide therapy</i> , 10.4274/mirt.galenos.2025.32815. Advance online publication. https://doi.org/10.4274/mirt.galenos.2025.32815
Link to published version	10.4274/mirt.galenos.2025.32815
Item License	https://creativecommons.org/licenses/by-nc-nd/4.0/
Date archived on GERR	2025-08-08T13:37:52Z



Penile Metastasis from Prostate Cancer: Detection on ¹⁸F-PSMA-1007 PET/CT

Prostat Kanserinden Kaynaklanan Penis Metastazı: ¹⁸F-PSMA-1007 PET/CT ile Saptanması

✉ **Hend Komber**^{1,4}, ✉ **Ayah Nawwar**^{1,2,3}, ✉ **Julie Searle**^{2,4}, ✉ **Iain Lyburn**^{2,4,5}

¹University Hospitals Bristol and Weston NHS Foundation Trust, Clinic of Radiology, Bristol, UK

²Cobalt Medical Charity, Cheltenham, UK

³Cairo University Faculty of Medicine, Department of Clinical Oncology and Nuclear Medicine, Cairo, Egypt

⁴Gloucestershire Hospitals NHS Foundation Trust, Clinic of Radiology, Gloucestershire, UK

⁵Cranfield Forensic Institute, Cranfield University, Wiltshire, UK

Abstract

A 74-year-old man with a history of prostate cancer and rising prostate-specific antigen underwent ¹⁸F-prostate specific membrane antigen (PSMA)-1007 positron emission tomography/computed tomography for investigation of oligometastatic disease. There was evidence of PSMA avid local recurrence findings with pelvic and retroperitoneal nodal metastases and skeletal deposits. Although rare and could easily be mistaken for contamination, a small penile metastasis was found. This is associated with poor prognosis and could impact further management. This case highlights the importance of a detailed review of the penis, to ensure differentiation between urinary activity and pathological uptake.

Keywords: ¹⁸F-PSMA-1007 positron emission tomography/computed tomography, prostate cancer, penile metastasis

Öz

Prostat kanseri öyküsü olan ve prostat spesifik antijen düzeyi yükselen 74 yaşında bir erkek hastaya, oligometastatik hastalık araştırması için ¹⁸F-prostat-spesifik membran antijeni (PSMA)-1007 pozitron emisyon tomografi/bilgisayarlı tomografi uygulandı. PSMA avid lokal nüks, pelvik ve retroperitoneal nodal metastazlar ve kemik metastazları ile uyumlu tutulumlar saptandı. Nadir görülse ve kolayca kontaminasyonla karıştırılabilse de, küçük bir penis metastazı tespit edildi. Bu durum kötü prognozla ilişkilidir ve tedaviyi etkileyebilir. Bu olgu, idrar aktivitesi ile patolojik tutulum arasındaki ayrımı sağlamak için penisin detaylı bir şekilde incelenmesinin önemini vurgulamaktadır.

Anahtar Kelimeler: ¹⁸F-PSMA-1007 pozitron emisyon tomografi/bilgisayarlı tomografi, prostat kanseri, penis metastazı

Address for Correspondence: Hend Komber, University Hospitals Bristol and Weston NHS Foundation Trust, Clinic of Radiology, Bristol, UK

E-mail: hend.komber@nhs.net **ORCID ID:** orcid.org/0000-0003-1917-9437

Received: 03.07.2024 **Accepted:** 20.01.2025 **Epub:** 01.08.2025

Cite this article as: Komber H, Nawwar A, Searle J, Lyburn I. Penile metastasis from prostate cancer: detection on ¹⁸F-PSMA-1007 PET/CT. Mol Imaging Radionucl Ther. [Epub Ahead of Print]



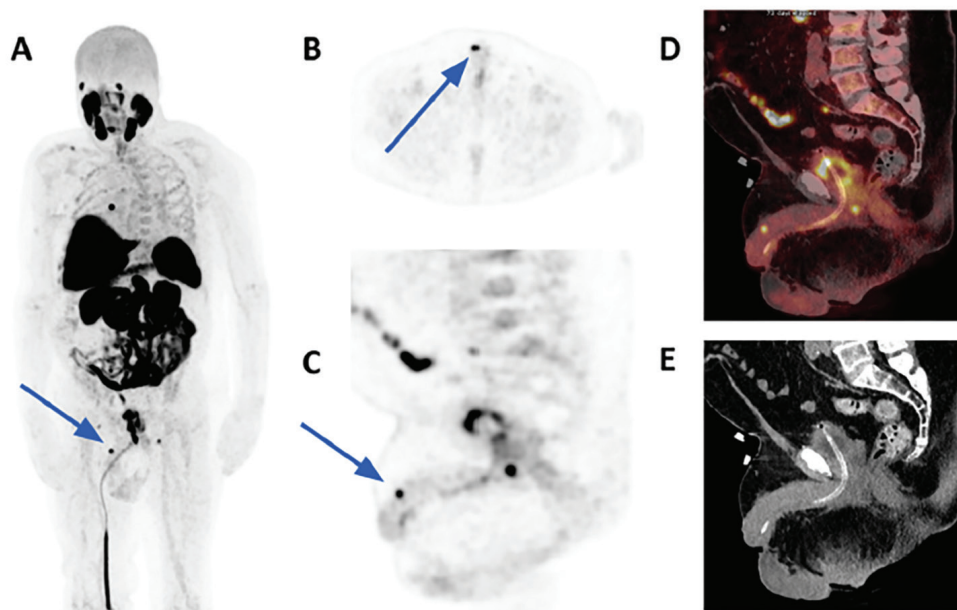


Figure 1. A 74-year-old man presents with recurrent prostate cancer and a prostate-specific antigen (PSA) level of 10 ng/mL (A) The left anterior oblique maximal intensity projection of ^{18}F -fluorodeoxyglucose, positron emission tomography/computed tomography (PET/CT), demonstrates prominent heterogeneous prostatic activity with intense focal activity in the right peripheral zone. A focus of uptake in the distal penile shaft was also seen (arrow). Axial, sagittal ^{18}F -prostate-specific membrane antigen (PSMA)-1007 PET and sagittal fused PET/CT (B, C and D) demonstrate the subcentimetric focus of tracer uptake in the right side of the penile shaft (arrows), which is not due to urinary contamination. Sagittal low-dose non-contrast CT (E) does not show an appreciable soft tissue lesion. ^{18}F -PSMA-1007 PET is fast becoming a key imaging modality in the assessment of biochemically recurrent prostate cancer (1), which can occur in up to 27% of patients who are managed by radical prostatectomy, and up to 55% of those managed by radiation therapy (2). A recent meta-analysis found that although the detection rate (DR) of ^{18}F -PSMA-1007 PET is dependent on serum PSA values, there is a good DR even at low PSA levels (0.5 ng/mL) (1). As expected, local relapse, regional lymph node, distant lymph node, and bone metastases are the most frequent sites of metastases (1), with a significantly higher number of positive findings when compared to conventional CT (3). Penile metastases are rare, usually presenting as part of advanced disease, and indicate poor prognosis, with half of the patients dying within one year of diagnosis (4). The primary malignancies involved are predominantly urological (bladder and prostate cancers), but also, less commonly, gastrointestinal and lung cancers (4). Awareness of the penis as a rare site of metastasis is important to avoid misdiagnosis with other non-malignant conditions (5). Penile metastases can present clinically with malignant priapism and are detectable on PSMA PET/CT (6). Penile metastases from prostate cancer have also been detected on ^{18}F -choline PET (7,8).

To our knowledge, there has been one case report of a penile metastasis from prostate cancer detected on ^{18}F -PSMA PET, this was a case of a solitary penile metastasis found on baseline staging in a patient with prostate cancer and PSA>90 ng/mL (9). Our case describes an unexpected example of a ^{18}F -PSMA avid penile deposit, as part of multifocal recurrence of prostate cancer in a patient with suspected recurrence due to rising PSA. This is associated with extremely poor prognosis, with an average survival of 9 months (10).

Ethics

Informed Consent: The patient has given permission for anonymised imaging and clinical information to be used for teaching, audit, research and publications including social media.

Footnotes

Authorship Contributions

Surgical and Medical Practices: A.N, J.S, I.L, Concept: A.N, J.S, I.L, Design: H.K, A.N, J.S, I.L, Data Collection or Processing: H.K, A.N, J.S, I.L, Analysis or Interpretation: H.K, A.N, J.S, I.L, Literature Search: H.K., Writing: H.K, A.N, J.S, I.L.

Conflict of Interest: No conflicts of interest were declared by the authors.

Financial Disclosure: The authors declare that this study has received no financial support.

References

- Ferrari M, Treglia G. ^{18}F -PSMA-1007 PET in biochemical recurrent prostate cancer: an updated meta-analysis. *Contrast Media Mol Imaging*. 2021;2021:3502389.
- Cornford P, van den Bergh RCN, Briers E, Van den Broeck T, Cumberbatch MG, De Santis M, Fanti S, Fossati N, Gandaglia G, Gillessen S, Grivas N, Grummet J, Henry AM, der Kwast THV, Lam TB, Lardas M, Liew M, Mason MD, Moris L, Oprea-Lager DE, der Poel HGV, Rouvière O, Schoots IG, Tilki D, Wiegel T, Willemse PM, Mottet N. EAU-EANM-ESTRO-ESUR-SIOG guidelines on prostate cancer. Part II-2020 update: treatment of relapsing and metastatic prostate cancer. *Eur Urol*. 2021;79:263-282.

3. Morawitz J, Kirchner J, Lakes J, Bruckmann NM, Mamlins E, Hiester A, Aissa J, Loberg C, Schimmöller L, Arsov C, Antke C, Albers P, Antoch G, Sawicki LM. PSMA PET/CT vs. CT alone in newly diagnosed biochemical recurrence of prostate cancer after radical prostatectomy: comparison of detection rates and therapeutic implications. *Eur J Radiol.* 2021;136:109556.
4. Zhang K, Da J, Yao HJ, Zheng DC, Cai ZK, Jiang YQ, Xu MX, Wang Z. Metastatic tumors of the penis: a report of 8 cases and review of the literature. *Medicine (Baltimore).* 2015;94:e132.
5. Dai Y, Shi BL, Zhang J, Liu SN, Jia YT. Penile metastasis from prostate cancer misdiagnosed as Peyronie disease: a case report. *Sex Med.* 2023;11:qfac011.
6. Kamaleshwaran KK, Balasundararaj BK, Jose R, Shinto AS. Penile metastasis from prostate cancer presenting as malignant priapism detected using Gallium-68 prostate-specific membrane antigen positron emission tomography/computed tomography. *Indian J Nucl Med.* 2018;33:57-58.
7. Hodolić M, Fettich J, Cimitan M, Kragelj B, Goldsmith SJ. Unusual F-18 choline uptake in penile metastasis from prostate cancer. *Clin Nucl Med.* 2012;37:e89-e90.
8. Bianchi D, Rizzo A, Bonacina M, Zaniboni A, Savelli G. penile metastasis from prostate cancer detected by 18f-fluorocholine PET/CT. *Clin Nucl Med.* 2021;46:e38-e39.
9. Dhull VS, Kshirsagar P, Chowhan M, Patil SC. Solitary penile metastasis from prostate cancer on ¹⁸f-prostate-specific membrane antigen positron emission tomography/computed tomography. *Indian J Nucl Med.* 2022;37:402-403.
10. Rohan V, Hanji A, Patel J, Goswami J, Tankshali R. Penile metastases from prostate cancer. *Urol J.* 2009;6:217-219.